

Original article

Soft tissue changes: a comparison between changes caused by the construction bite and by successful treatment with a modified Twin-block appliance

Erfan Salloum¹, Declan T. Millett¹, Niamh Kelly¹, Grant T. McIntyre² and Michael S. Cronin³

¹Cork University Dental School and Hospital, University College Cork, Cork, Ireland, ²Dundee Dental Hospital, Dundee, UK and ³Department of Statistics, Western Gateway, University College Cork, Cork, Ireland

Correspondence to: Declan T. Millett, Cork University Dental School and Hospital, University College Cork, Cork, Ireland.
E-mail: d.millett@ucc.ie

Summary

Background/objectives: Functional appliances are commonly used to correct Class II malocclusion. This study aimed to compare the facial soft tissue changes in Caucasians between pre-treatment and with the construction bite versus pre-treatment and completion of treatment with a modified Twin-block appliance (MTBA).

Materials and methods: Fifty-eight Caucasian subjects with Class II division 1 malocclusion had 3D stereophotogrammetric images captured pre-treatment (T1), with the construction bite (T2), and on completion of MTBA treatment (T3). Twenty-six landmarks were located on each image and 10% were re-landmarked 1 month later. Soft-tissue linear and volumetric changes (T1–T2 and T1–T3) were analyzed using linear mixed effect models (SAS® Version 9.4, www.sas.com).

Results: Forty-seven subjects [mean age 13.2 (SD 1.7) years] completed treatment [mean duration 9.8 (SD 3.8) months]. Differences between the changes from T1 to T2 versus T1 to T3 for upper facial and upper lip landmarks were insignificant (all $P > 0.05$) except for nasion, orbitale right, pronasale, and subnasale. For the same comparisons, lower lip and chin landmarks changed significantly (all $P < 0.05$) as did facial soft tissue volume ($P < 0.0001$).

Limitations: There was no control group.

Conclusion: The facial soft tissue changes from pre-treatment to with the construction bite were considerably more than those from pre-treatment to completion of treatment with a MTBA.

Implication: With MTBA treatment, the soft tissue changes from pre-treatment to with the construction bite *in situ*, overestimate those from pre- to post-treatment.

Introduction

Prominent upper incisors and an increased overjet are associated with poor facial aesthetics (1), bullying (2), and an increased risk of incisor trauma (3). Functional appliances have proved particularly

popular for the correction of Class II malocclusion in growing children and they also reduce the incidence of incisal trauma (4, 5).

The skeletal and dental effects of the Twin-block and other functional appliances have been investigated using lateral cephalometry (6–8). Only mandibular changes greater than 2 mm, however, have

been deemed clinically significant (9). Flores-Mir and Major (10) highlighted the need for 3D quantification of the soft-tissue effects of functional appliances. Using colour mapping, approximately 2 mm advancement of the soft-tissue chin has been identified with these appliances (11–13).

For construction of a Twin-block appliance, the mandible is postured forwards and the position recorded using a wax rim (14–15). Clark (16) advocated reduction of the overjet by 5–7 mm with 3–5 mm inter-occlusal clearance at the premolar region whilst Shah and Sandler (15) recommended at least 7–8 mm opening in the same area. The use of the 'Projet Bite' gauge may also be used to record the postured mandibular position (17). Patients and their parents often ask if the facial soft tissue changes, observed from pre-treatment to with the construction bite *in situ*, will be seen on completion of Twin-block treatment. Currently, no research has addressed this question. The aim of this study was to compare the facial soft tissue changes between pre-treatment and with the construction bite versus those from pre-treatment to completion of treatment with a modified Twin-block appliance (MTBA). The null hypothesis tested was that the changes in facial soft tissues recorded between pre-treatment and with the construction bite were no different to those recorded between pre-treatment and the completion of treatment with a MTBA.

Material and methods

Based on previous work (13) where the median value for soft tissue chin point advancement was 3.71 mm (interquartile range: 1.4 and 5.71 mm), a sample size calculation determined that 46 subjects would have an 80% power at $P < 0.05$ to detect a clinically meaningful treatment difference of 2 mm in advancement of soft tissue pogonion from pre-treatment to with the construction bite versus pre-treatment to the completion of treatment with a MTBA.

Following ethical approval from the local Clinical Research Ethics Committee, consecutive subjects were recruited according to the following criteria:

- Class II division 1 malocclusion
- Overjet greater than 7 mm (18)
- Good oral hygiene
- Growing patient aged 11–14 years
- Willingness to co-operate

Subjects with poor oral hygiene or craniofacial anomalies were not recruited. Informed consent was obtained from each subject and their parent. All subjects were in the late mixed/permanent dentition. Patient gender, age, and overjet were noted but no matching according to gender was undertaken. Alginate impressions of the upper and lower dental arches were recorded for construction of each MTBA. A 4-mm white 'Projet Bite' gauge [Orthocare, (UK) Limited] was used with a thickened wax rim to register the mandibular incisors in an edge-to-edge relationship with the maxillary incisors or where this was not possible, the maximum comfortable protrusion.

The MTBA design was as follows: 0.7 mm Adams' clasps for all first permanent molars and first premolars with a 0.7-mm Southend clasp for the lower permanent central incisors. An upper midline expansion screw was incorporated with buccal blocks approximately 5 mm in height (Figure 1).

Three-dimensional stereophotogrammetric images were captured pre-treatment at rest (T1) and with the construction bite in place (T2). Projecting wax and plastic were trimmed flush with the teeth to avoid soft tissue distortion during imaging.

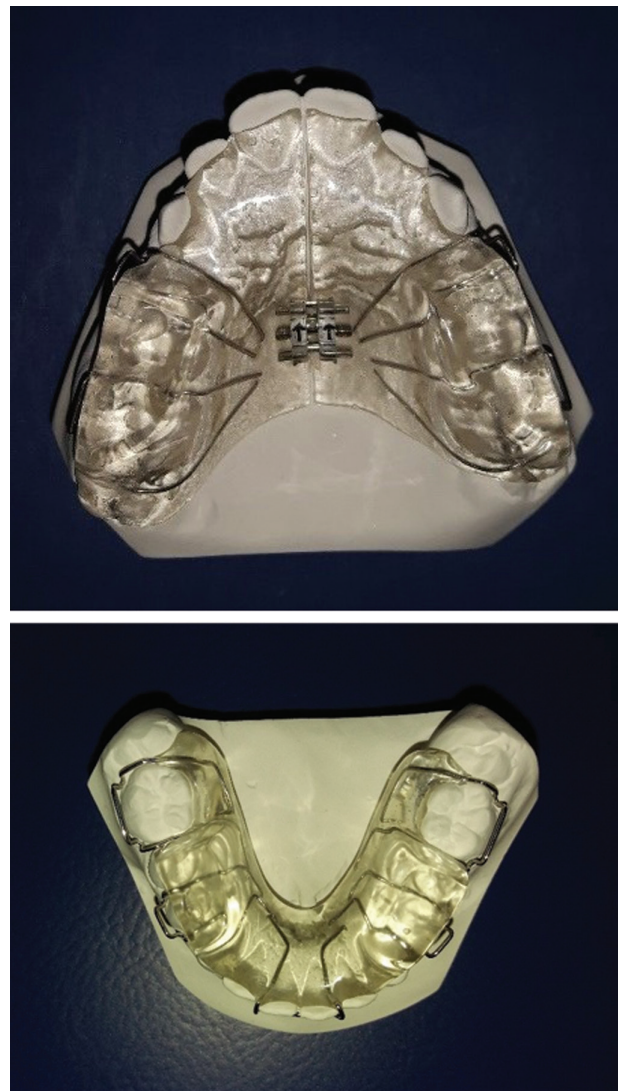

Figure 1. Design of MTBA used in this study.

Subjects were asked to wear the MTBA full-time; and to remove it only for contact sports, swimming, and for appliance hygiene. At the completion of treatment, when the incisor relationship was Class 1 (overjet 2–4 mm), another 3D image was captured at rest for each patient without the MTBA in place (T3).

All 3D images were recorded by one experienced operator. Each subject was seated in the centre of the DI3D system (www.di4d.com/systems/di3d-system) in natural head position, make-up removed, hair tied back with a hair band (when necessary); teeth were in occlusion for images recorded at T1 and T3. The DI3D system, which has high precision (mean error 0.057) (19), comprised four 10 megapixel Canon 1000D digital cameras mounted 85 cm apart on a supporting stand and converging at 97 cm from the face with 2 Esprit 500DX flashes connected to a Dell Optiplex 980 personal computer. This produced 3D facial surface images with highly detailed 20 megapixel texture maps. The system was calibrated using six images of a matt white sheet of card with matt black spheres, of known dimensions and located at known distances. System calibration was confirmed at the beginning of every week and re-calibrated if either the orientation of the cameras was changed or settings such as focus and aperture were adjusted. Following scanning, the 3D models were

created 1–2 minutes later. Image quality was checked while the subject was present. One operator subsequently landmarked all the 3D models (20, 21; Figure 2). In addition to calculation of method error, landmark reproducibility was determined by re-assessment of 10% of images 1 month after initial assessment. These images were chosen randomly across the three time points but the examiner was not blinded to the time point for this or for the main assessment as the facial profile changes were obvious between each time point.

For volumetric comparison of two images, T1 to T2 and T1 to T3, superimposition was undertaken. The software translated and rotated the coordinate system of the second image to achieve best fit onto the first, known as the Iterative Closest Points (ICP) technique. For this, corresponding patches were highlighted on both models and ICP registration established correspondence between data sets. Surface volumetric differences between the images were then accurately recorded by the software (22) and colour-coded as follows: blue—greater volume; red—lesser volume; green—no change, with the colour intensity indicating the magnitude of volumetric change. To minimise disturbance during registration, the forehead and bridge of nose, an area of the face unlikely to be affected by MTBA treatment, was used for superimposition (23).

Lateral cephalograms taken at T1 and T3 were analysed. The landmarks recorded are shown in Figure 3 along with the five soft tissue linear distances that were measured from a vertical reference line constructed through sella at 7 degrees to the sella-nasion line (24).

To determine the error in cephalometry, 20% of the radiographs were randomly selected and re-analysed 1 week after the initial assessment.

Statistical analysis

Intra-examiner reliability for mean 3D landmark and mean cephalometric errors were calculated using Dahlberg's formula (25)

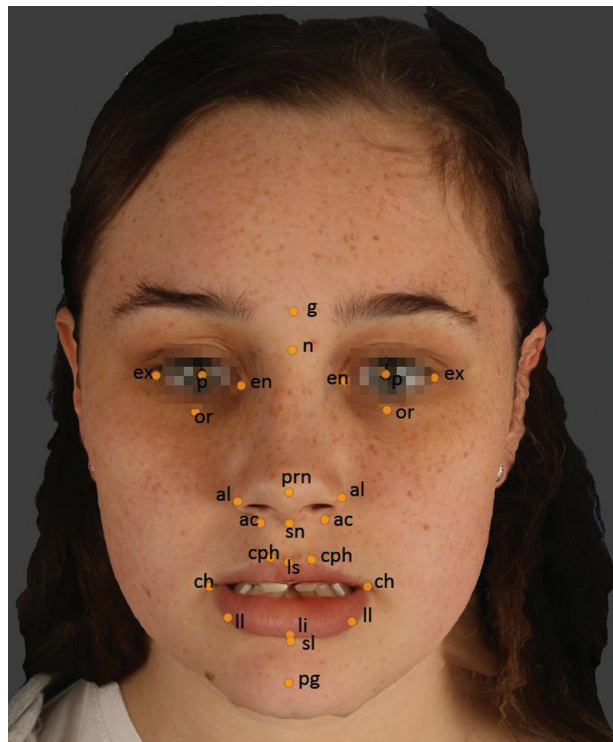


Figure 2. Landmarked facial image.

and a two-sample *t*-test ($P < 0.05$). Soft tissue linear and volumetric changes (from T1 to T2 and from T1 to T3) were compared using linear mixed effect models (SAS® Version 9.4, www.sas.com). Gender and time-point were included as fixed effects. Age and treatment duration were included as covariates with the subject included as a random effect. A variance components covariance matrix was applied and the adequacies of the models were assessed using residual analyses and transformations were applied if required.

Results

A total of 58 patients [mean age 13.2 (SD 1.7) years] were fitted with a MTBA. Eleven patients (19%) did not complete treatment due to poor compliance ($n = 3$), unfavourable growth ($n = 4$), change of treatment plan ($n = 2$), or failure to attend ($n = 2$).

Data for 47 subjects [18 females and 29 males; mean age 13.4 years, (SD 1.22)] who completed the study were analyzed at T3 [mean treatment duration 9.8 (SD 3.8) months]. There were no differences between the male and female subjects in terms of pre-treatment age ($P = 0.52$), pre-treatment skeletal, and dental parameters (Table 1; all values $P > 0.05$), pre-treatment overjet ($P = 0.54$), or length of treatment ($P = 0.52$). Therefore, male and female subjects were analyzed as a single group. In addition, there was no difference in the amount of protrusion for the 41 patients that were postured edge-to-edge [mean 9.56 (SD 2.13) mm] and the 6 patients that were postured maximally [mean 9.0 (SD 1.58) mm] ($P = 0.323$). There was also no difference in the overjet at the completion of MTBA treatment (T3) between those patients postured edge-to-edge and those postured maximally ($P = 0.399$). Three patients required the appliance to be repaired during treatment but this did not affect treatment duration (T1 to T3).

Intra-observer reproducibility of 3D landmarking was acceptable; the mean landmark identification error was good at 0.625 mm.

Comparisons of the changes in upper facial and upper lip landmarks, from T1 to T2 versus T1 to T3, were non-significant (all $P > 0.05$) except for nasion, orbitale right, pronasale, and subnasale (all $P < 0.05$) (Table 2). The changes for the lower lip and chin landmarks were statistically and clinically significant (all $P < 0.05$). The mean overall forward movement of the lower facial soft tissue landmarks from T1 to T3 was less than that observed from T1 to T2 (Figure 4) with labiale inferius advancing most (5.1 mm), followed by sublabiale (4.9 mm), lower lip right (4.4 mm), pogonion (4.3 mm), lower lip left (4.2 mm), chelion left (3.4 mm), and chelion right (3.1 mm) (Table 2). The mean overall changes in the *x*, *y*, and *z* planes for each of the lower facial landmarks are given in Table 3. On average from T1 to T3, labiale inferius moved forward by 1.83 mm compared with 4.79 mm from T1 to T2. Average corresponding movement for pogonion for the same time intervals, indicated forward movement of 2.06 mm (T1 to T3) compared with 3.26 mm (T1 to T2).

For all cephalometric measurements, the Dahlberg value was less than 1. No statistically significant systematic error was found for any of the cephalometric measurements ($P < 0.05$). Overall, these cephalometric findings indicate change principally in mandibular and lower incisor position (SNB and LII, respectively) with lesser change observed in the mean upper incisor position (UII). The mean soft tissue linear changes were greatest for sublabiale, followed by labiale inferius and pogonion.

The mean soft tissue volume change from T1 to T2 was 37.12 (SD 15.24) cm³ and from T1 to T3 was 22.24 (SD 16.73) cm³ with this 40% difference being significant ($P < 0.0001$). Figure 5 indicates

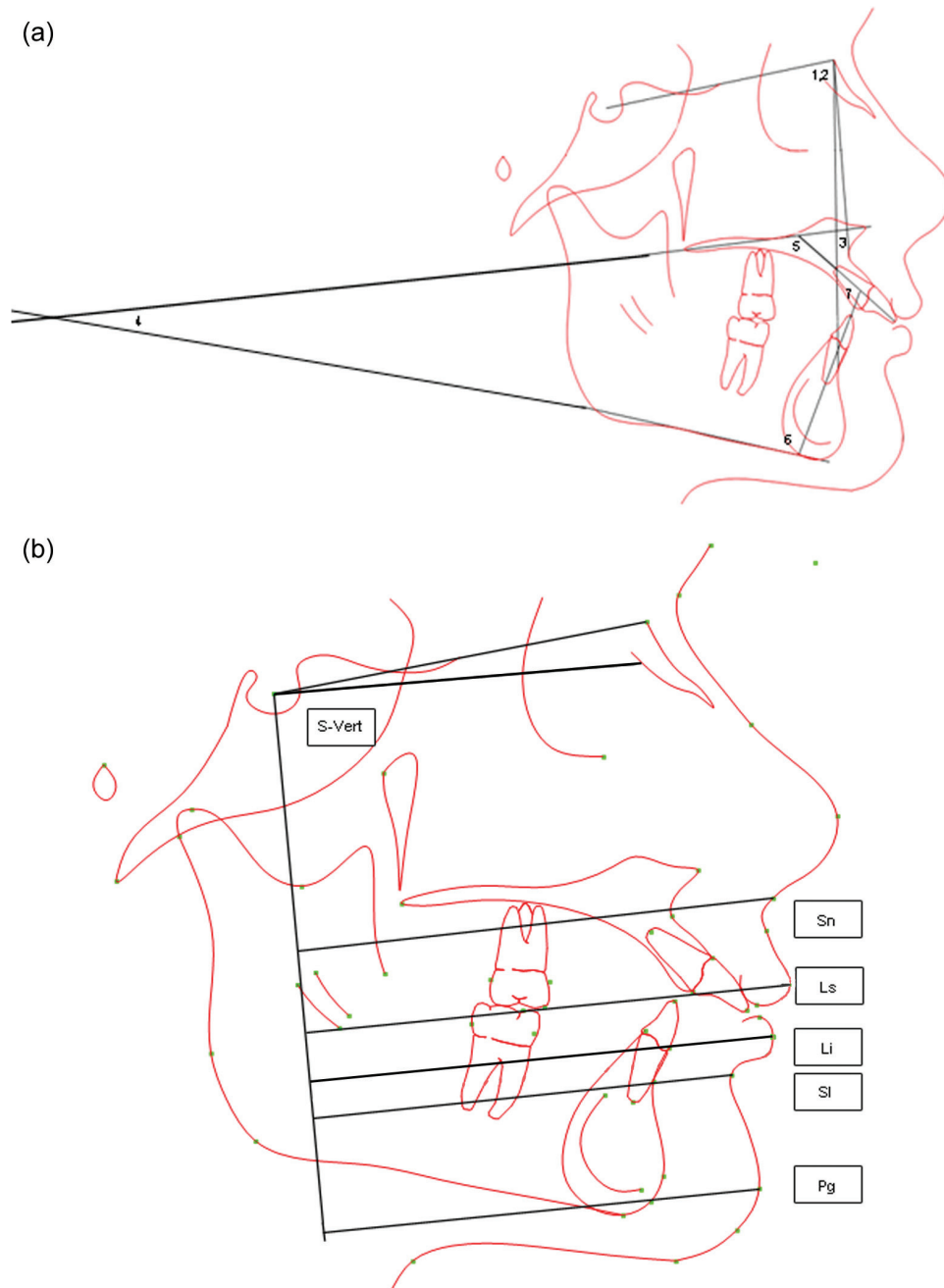


Figure 3. (a) Angular cephalometric measurements: 1, Sella-Nasion-A point (SNA); 2, Sella-Nasion-B point (SNB); 3, A point-Nasion-B point (ANB); 4, Maxillary-Mandibular planes angle (MMPA); 5, Upper Incisor-Maxillary Plane (UI); 6, Lower Incisor-Mandibular Plane (LI); 7, Interincisal Angle (IIA). (b) Linear cephalometric measurements from S-Vert (S-vertical) to the following points: Sn, Subnasale; Ls, Labiale Superius; Li, Labiale Inferius; Sl, Sublabiale; Pg, Pogonion.

forward differences in blue with areas of no change shown in green. The areas in yellow/red indicate changes at the temporomandibular joint and in the temporal musculature.

Discussion

This cohort study found that the changes in both lower lip and chin soft tissue landmarks and facial soft tissue volume from pre-treatment to with the construction bite were greater than those recorded from pre-treatment to completion of treatment with a MTBA. The null hypothesis, was, therefore, rejected for these lower facial landmarks only but not for those related to upper lip landmarks; except for four

landmarks (nasion, orbitale right, pronasale, subnasale), the null hypothesis was accepted for upper facial landmarks. Subjects were all Southern Irish and were recruited at one centre; the construction bite, appliance design, and treatment protocols were all standardized. Our final sample of 47 successful cases is similar to other 3D imaging cohort studies that have evaluated functional appliance outcomes (11–13, 26) and the dropout rate of 19% is akin to previous clinical trials with other designs of MTBA (14, 18). The mean treatment duration of 9.8 months was also similar to other studies (27–29).

No controls were recruited as this study focused on evaluation of the 3D soft tissue changes from pre-treatment to with the construction bite versus those from pre-treatment to the outcome of treatment with

Table 1. Mean angular and linear cephalometric parameters for the combined male and female samples: T1, T3, and T1 to T3.

		T1	T3	T1 to T3
		Mean (SD)	Mean (SD)	
Angular (Degrees)	SNA	82.33 (4.17)	82.38 (4.66)	0.05
	SNB	76.68 (5.12)	79.69 (4.38)	3.01
	ANB	5.21 (2.52)	2.68 (2.36)	-2.53
	MMPA	26.45 (4.93)	26.26 (5.21)	-0.19
	UII	119.01 (14.13)	116.63 (5.32)	-2.38
	LII	92.40 (6.74)	95.58 (8.43)	3.18
Linear (mm)	IIA	119.4 (9.52)	121.85 (9.04)	2.45
	Vertical to pogonion	71.86 (7.80)	75.98 (7.86)	4.12
	Vertical to sublabiale	70.45 (6.57)	75.54 (7.15)	5.09
	Vertical to labiale inferius	80.23 (5.99)	84.55 (6.42)	4.32
	Vertical to labiale superius	86.74 (5.75)	87.66 (5.75)	0.92
	Vertical to subnasale	85.25 (4.71)	87.13 (4.89)	1.88

Table 2. Mean (SD) 3D linear soft-tissue differences between T1 to T2 versus T1 to T3 for the combined male and female samples.

		T1 to T2		T1 to T3		P Value
		Mean (mm)	SD	Mean (mm)	SD	
Upper face	Glabella	0.45	0.43	0.48	0.41	0.6819
	Nasion	0.49	0.30	0.33	0.19	0.0002
	Exocanthion right	1.00	1.05	1.15	0.90	0.3910
	Mid pupil right	0.82	0.71	0.79	0.64	0.6803
	Orbitale right	0.72	0.45	0.61	0.43	0.0466
	Endocantion right	0.65	0.44	0.62	0.46	0.5529
	Endocantion left	0.61	0.46	0.73	0.50	0.2873
	Mid pupil left	0.77	0.61	0.78	0.48	0.9780
	Orbitale left	0.72	0.51	0.93	0.61	0.0840
	Exocanthion left	1.06	0.65	1.08	0.73	0.8432
	Pronasale	0.67	0.35	0.55	0.38	0.0399
	Subnasale	1.15	0.96	1.77	1.35	0.0289
	Alar curvature right	1.06	1.14	1.22	0.91	0.3225
	Alar curvature left	1.07	0.94	1.21	0.83	0.3209
Lower face	Alare right	1.59	1.29	1.75	1.38	0.5623
	Alare left	2.56	2.67	2.35	2.31	0.9685
	Chellion right	5.92	2.62	2.82	1.76	<.0001
	Christa philtri right	2.06	1.60	2.12	1.49	0.5551
	Labiale superius	2.25	1.77	2.19	1.54	0.8259
	Christa philtri left	2.13	1.70	2.08	1.51	0.9259
	Chellion left	6.02	2.86	2.58	1.77	<.0001
	Labiale inferius	9.32	2.77	4.20	2.17	<.0001
	Lower lip right	7.74	2.62	3.32	1.87	<.0001
	Lower lip left	7.68	2.74	3.48	1.98	<.0001
Sublabiale	9.80	3.20	4.92	2.39	<.0001	
Pogonion	8.47	3.01	4.13	2.48	<.0001	

Bold *P* values indicate significant difference between T1 to T2 versus T1 to T3.

a MTBA using a prospective cohort study design. The cephalometric skeletal and dental changes mirrored those of another clinical trial of a MTBA (30). The appliance design used in that study, however, was slightly different to the one used in the study reported here.

Accurate recording of the construction bite is important for functional appliance treatment (14). With the construction bite *in situ*, the magnitude of movement for all paired landmarks was similar confirming symmetrical advancement. Landmarking of 3D images was undertaken by one experienced operator using validated landmarks (20). The mean intra-observer landmark identification error was good at 0.625 mm (29). The changes in position of the upper facial soft tissue

landmarks between T1 to T2 and T1 to T3 were minimal (less than 1 mm). This could be the result of a combination of maxillary growth and variability in soft tissue landmark identification of around 1–2 mm (22) and is not clinically significant (27). Labiale superius and the christa philtri right and left landmarks advanced by a non-significant mean of around 2 mm and contrasts with the cephalometric findings of Quintao *et al.* (26) who reported retraction of the upper lip with a Twin-block appliance in a Brazilian sample. Possible reasons for the upper lip differences between these studies may be due to variation in landmarks, method of superimposition, or design of appliance. The cephalometric changes reported in the present study indicate change

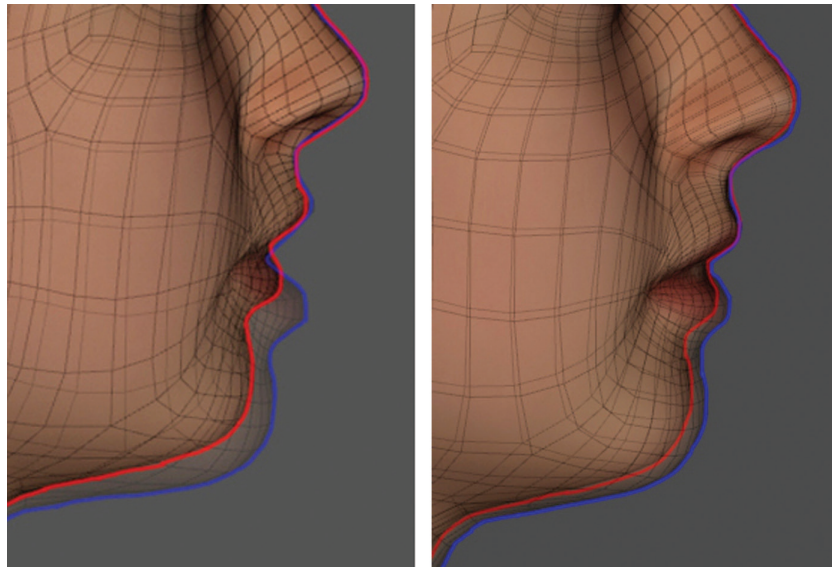


Figure 4. 3D soft-tissue profile changes: (a) T1 to T2, (b) T1 to T3.

Table 3. Mean changes in x, y, and z coordinates of lower facial landmarks from T1 to T2 and T1 to T3 for the combined male and female samples.

	T1 to T2			T1 to T3			
	x	y	z	x	y	z	z
Cheilion right	0.3631	-3.1851	2.4595	0.0237	-0.8792	0.4080	
Christa philtri right	-0.2871	0.5649	0.6954	-0.0262	-1.0241	-1.1535	
Labiale superius	-0.2277	0.6698	0.8877	-0.0127	-0.8858	-1.1665	
Christa philtri left	-0.2877	0.4427	0.8812	-0.0844	-0.9288	-1.0423	
Cheilion left	-0.5414	-3.3798	2.5230	0.1334	-0.6120	0.2331	
Labiale inferius	-0.0007	-6.6593	4.7853	0.1576	-1.6964	1.8262	
Lower lip right	-0.9087	-5.2412	3.2791	-0.1651	-0.9966	1.2442	
Lower lip left	1.3292	-5.3152	2.8788	0.5753	-1.1075	1.2632	
Sublabiale	0.0687	-7.6851	3.8507	0.1913	-2.6019	2.3929	
Pogonion	-0.0687	-6.2193	3.2643	-0.0055	-0.9761	2.0556	

X axis change = horizontal change; Y axis change = vertical change; Z axis change = anteroposterior change. Positive value of change from T1 to T2 and from T1 to T3 for x coordinate indicates a left shift, for y axis indicates an upward shift and for z axis indicates a forward shift. Negative value of change from T1 to T2 and from T1 to T3 for x coordinate indicates a right shift, for y axis indicates a downward shift and for z axis indicates a backwards shift.

in mandibular position as well as upper and lower incisor inclination. There was a mean increase in mandibular protrusion of approximately 3 degrees which corresponds to almost a 4-mm increase in soft tissue chin point projection. The soft tissue changes at the lower lip and chin landmarks from T1 to T3 recorded in the current study were similar to those of previous investigations using colour mapping (11–13, 22). At between 3 and 5 mm, these soft tissue changes were clinically significant (greater than 2 mm) and these exceed the hard tissue mandibular changes produced by functional appliances (9). The greater advancement of sublabiale than pogonion from T1 to T3 was most likely due to lower incisor proclination. Nevertheless, a significant reduction in the comparative changes in both the forward displacement of the lower lip and chin landmarks (50–57% less) and the facial soft tissue volume (40% less) was recorded between T1 to T2 versus T1 to T3. These lower facial soft tissue differences were most likely due to repositioning of the mandibular condyle and recoil of the soft tissue stretch in all three dimensions. An increase in mandibular length has been quantified with functional appliances at around 2

mm (9). Had this cohort been compared to age and gender matched controls, the soft tissue effects are likely to have been less as growth changes augmented those of the appliance.

This study only assessed successful cases and did not include an intention to treat analysis incorporating those that dropped out or changed treatment plan. As such the results are only applicable to cases that successfully complete MTBA treatment. From this effectiveness study, patients and parents may be advised that, not accounting for growth, the soft tissue changes in the lower lip and chin from pre-treatment to completion of treatment with a MTBA will be about half of the changes observed from pre-treatment to with the construction bite; the changes in facial soft tissue volume will be less.

Conclusion

The facial soft tissue changes from pre-treatment to with the construction bite were considerably more than those from pre-treatment to completion of treatment with a MTBA.

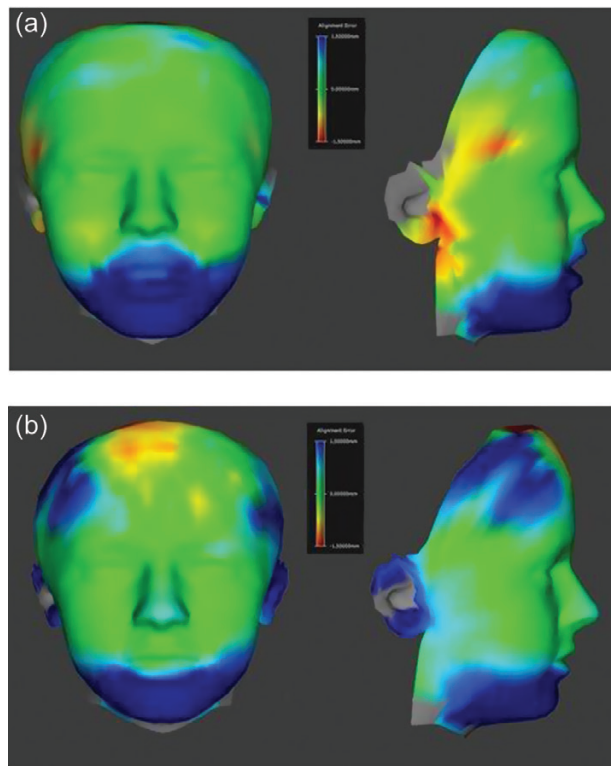


Figure 5. Mean 3D volume changes: (a) T1 to T2 and (b) T1 to T3. Key—blue: changes > 1.5 cm³; green: no changes; red/yellow: changes in the opposite direction to blue changes.

Conflict of Interest statement

None to declare.

References

- O'Brien, K., et al. (2009) Early treatment for Class II malocclusion and perceived improvements in facial profile. *American Journal of Orthodontics and Dentofacial Orthopedics*, 135, 580–585.
- Seehra, J., Newton, J.T. and Dibiase, A.T. (2013) Interceptive orthodontic treatment in bullied adolescents and its impact on self-esteem and oral-health-related quality of life. *European Journal of Orthodontics*, 35, 615–621.
- Petti, S. (2015) Over two hundred million injuries to anterior teeth attributable to large overjet: a meta-analysis. *Dental Traumatology*, 31, 1–8.
- Thiruvengkatachari, B., Harrison, J., Worthington, H. and O'Brien, K. (2015) Early orthodontic treatment for Class II malocclusion reduces the chance of incisal trauma: Results of a Cochrane systematic review. *American Journal of Orthodontics and Dentofacial Orthopedics*, 148, 47–59.
- DiBiase, A.T., Cobourne, M.T. and Lee, R.T. (2015) The use of functional appliances in contemporary orthodontic practice. *British Dental Journal*, 218, 123–128.
- Tümer, N. and Gültan, A.S. (1999) Comparison of the effects of mono-block and twin-block appliances on the skeletal and dentoalveolar structures. *American Journal of Orthodontics and Dentofacial Orthopedics*, 116, 460–468.
- Sidlauskas, A. (2005) Clinical effectiveness of the Twin block appliance in the treatment of Class II Division 1 malocclusion. *Stomatologija*, 7, 7–10.
- Singh, M.G., Vashisth, P., Chaudhary, S. and Sinha, A. (2012) Early treatment outcomes of class II malocclusion with twin-block facial profile and cephalometric changes. *Journal of Oral Biology and Craniofacial Research*, 2, 61–66.
- Cozza, P., Baccetti, T., Franchi, L., De Toffol, L. and McNamara, J.A. Jr. (2006) Mandibular changes produced by functional appliances in Class II malocclusion: a systematic review. *American Journal of Orthodontics and Dentofacial Orthopedics*, 129, 599.e1–12; discussion e1.
- Flores-Mir, C. and Major, P.W. (2006) Cephalometric facial soft tissue changes with the twin block appliance in Class II division 1 malocclusion patients. A systematic review. *The Angle Orthodontist*, 76, 876–881.
- McDonagh, S., Moss, J.P., Goodwin, P. and Lee, R.T. (2001) A prospective optical surface scanning and cephalometric assessment of the effect of functional appliances on the soft tissues. *European Journal of Orthodontics*, 23, 115–126.
- Sharma, A.A. and Lee, R.T. (2005) Prospective clinical trial comparing the effects of conventional Twin-block and mini-block appliances: part 2. Soft tissue changes. *American Journal of Orthodontics and Dentofacial Orthopedics*, 127, 473–482.
- Lee, R.T., Kyi, C.S. and Mack, G.J. (2007) A controlled clinical trial of the effects of the Twin Block and Dynamax appliances on the hard and soft tissues. *European Journal of Orthodontics*, 29, 272–282.
- Banks, P., Wright, J. and O'Brien, K. (2004) Incremental versus maximum bite advancement during twin-block therapy: a randomized controlled clinical trial. *American Journal of Orthodontics and Dentofacial Orthopedics*, 126, 583–588.
- Shah, A.A. and Sandler, J. (2009) How to take a wax bite for a Twin Block appliance. *Journal of Orthodontics*, 36, 10–12.
- Clark, W.J. (1988) The twin block technique. A functional orthopedic appliance system. *American Journal of Orthodontics and Dentofacial Orthopedics*, 93, 1–18.
- Clark, W. (2010) Design and management of Twin Blocks: reflections after 30 years of clinical use. *Journal of Orthodontics*, 37, 209–216.
- O'Brien, K., et al. (2003) Effectiveness of early orthodontic treatment with the Twin-block appliance: a multicenter, randomized, controlled trial. Part 1: dental and skeletal effects. *American Journal of Orthodontics and Dentofacial Orthopedics*, 124, 234–43; quiz 339.
- Winder, R.J., Darvann, T.A., McKnight, W., Magee, J.D. and Ramsay-Baggs, P. (2008) Technical validation of the Di3D stereophotogrammetry surface imaging system. *The British Journal of Oral and Maxillofacial Surgery*, 46, 33–37.
- Farkas, L.G. (1994) *Anthropometry of the Head and Face*. Springer Harbor Laboratory Press, Cold Spring Harbor, NY.
- Sawyer, A.R., See, M. and Nduka, C. (2009) Assessment of the reproducibility of facial expressions with 3-D stereophotogrammetry. *Otolaryngology–Head and Neck Surgery*, 140, 76–81.
- Hajeer, M.Y., Mao, Z., Millett, D.T., Ayoub, A.F. and Siebert, J.P. (2005) A new three-dimensional method of assessing facial volumetric changes after orthognathic treatment. *Cleft Palate Craniofacial Journal*, 42, 113–120.
- Ismail, S.F. and Moss, J.P. (2002) The three-dimensional effects of orthodontic treatment on the facial soft tissues—a preliminary study. *British Dental Journal*, 192, 104–108.
- Burstone, C.J., James, R.B., Legan, H., Murphy, G.A. and Norton, L.A. (1978) Cephalometrics for orthognathic surgery. *Journal of Oral Surgery (American Dental Association: 1965)*, 36, 269–277.
- Dahlberg, G. (1940) *Statistical Methods for Medical and Biological Students*. George Allen & Unwin Ltd, London, pp. 122–132.
- Quintão, C., Helena, I., Brunharo, V.P., Menezes, R.C. and Almeida, M.A. (2006) Soft tissue facial profile changes following functional appliance therapy. *European Journal of Orthodontics*, 28, 35–41.
- Tulloch, J.F., Phillips, C., Koch, G. and Proffit, W.R. (1997) The effect of early intervention on skeletal pattern in Class II malocclusion: a randomized clinical trial. *American Journal of Orthodontics and Dentofacial Orthopedics*, 111, 391–400.
- Varlik, S.K., Gültan, A. and Tümer, N. (2008) Comparison of the effects of Twin Block and activator treatment on the soft tissue profile. *European Journal of Orthodontics*, 30, 128–134.
- Aynechi, N., Larson, B.E., Leon-Salazar, V. and Beiraghi, S. (2011) Accuracy and precision of a 3D anthropometric facial analysis with and without landmark labeling before image acquisition. *The Angle Orthodontist*, 81, 245–252.
- Yaqoob, O., Dibiase, A.T., Fleming, P.S. and Cobourne, M.T. (2012) Use of the Clark Twin Block functional appliance with and without an upper labial bow: a randomized controlled trial. *The Angle Orthodontist*, 82, 363–369.